

Original Article

# Prevalence of Pregnancy Tumor in Tripoli, Libya: A Multicenter Cross-Sectional Study

Raja Barioun<sup>1\*</sup>, Dunya Ben Sofia<sup>2</sup>, Asmaa Shanab<sup>2</sup><sup>1</sup>Department of Periodontology, Faculty of Dentistry, University of Tripoli, Tripoli, Libya.<sup>2</sup>Department of Oral Medicine, Oral Pathology and Oral & Maxillofacial Surgery, Faculty of Dentistry, University of Tripoli, Tripoli, Libya.Corresponding Email: [r.baryoun@uot.edu.ly](mailto:r.baryoun@uot.edu.ly)

## ABSTRACT

**Background and objectives.** Pyogenic granuloma (pregnancy tumor) is one of the gingival inflammatory changes with an increased incidence during pregnancy. The present study aimed to determine the prevalence and characteristics of pregnancy tumors in pregnant Libyan women in Tripoli, Libya. **Methods.** In this descriptive cross-sectional study, pregnant Libyan women were assessed at the National Heart Center-Tajoura, Jalaa Maternity Hospital, and Tripoli University Hospital during the period from August to November 2023. Data were collected through interviewing and clinical examination of the participants and filling out a data form. **Results.** During four months period, of 402 pregnant Libyan women, 4 (1.0%) were clinically diagnosed with pregnancy tumors. The four cases were in their third trimester of pregnancy. Half (50%) of pregnancy tumor cases were more than 30 years old, and the other half (50%) were early 20 years old. The gingiva was the only site of the lesions, and were observed equally in the maxilla and the mandible. All pregnancy tumor cases have calculus on their teeth, bleeding gums, and poor oral hygiene status. All lesions were sessile had lobulated surfaces, and showed spontaneous and provoked bleeding. **Conclusions.** Although the results of this study indicate that the prevalence of pregnancy tumors in pregnant Libyan women is considered low (1.0%), oral health education programs are very important during pregnancy, and if pregnant women notice any abnormal growth during pregnancy in their mouth, they should consult a dentist.

**Keywords:** Prevalence, Pyogenic Granuloma, Pregnancy Tumor, Libya.**Citation:** Barioun R, Ben sofia D, Shanab A. Prevalence of Pregnancy Tumor in Tripoli, Libya: A Multicenter Cross-Sectional Study. *Khalij-Libya J Dent Med Res.* 2024;8(1):95–103. <https://doi.org/10.47705/kjdmr.2481014>**Received:** 11/02/24; **accepted:** 19/05/24; **published:** 29/05/24Copyright © Khalij-Libya Journal (KJDMR) 2024. Open Access. Some rights reserved. This work is available under the CC BY-NC-SA 3.0 IGO license <https://creativecommons.org/licenses/by-nc-sa/3.0/igo>

**الخلفية والأهداف:** الورم الحبيبي القيحي (ورم الحمل) هو أحد التغيرات الالتهابية اللثوية الذي يزداد حدوثه أثناء الحمل. تهدف الدراسة الحالية إلى تحديد مدى انتشار وخصائص أورام الحمل لدى النساء الليبيات الحوامل في طرابلس، ليبيا. **الطريقة:** في هذه الدراسة الوصفية المقطعية، تم تقييم النساء الليبيات الحوامل في المركز الوطني للقلب - تاجوراء ومستشفى الجلاء للولادة ومستشفى طرابلس الجامعي خلال الفترة من أغسطس إلى نوفمبر 2023. تم جمع البيانات من خلال إجراء المقابلات والفحص السريري للمشاركة وملء نموذج البيانات. **النتائج:** خلال فترة أربع أشهر، من بين 402 امرأة ليبية حامل، تم تشخيص 4 حالات (1.0%) سريريا بأورام الحمل. وكانت الحالات في الثلث الثالث من الحمل. كان نصف (50%) الحالات عمرهن أكثر من 30 عاماً، والنصف الآخر (50%) كان عمرهن في أوائل 20 عاماً. كانت اللثة هي الموقع الوحيد للورم. ولوحظ بالتساوي في الفك العلوي والفك السفلي. جميع حالات أورام الحمل لديها ترسبات على أسنانهن، ونزيف اللثة وحالة نظافة الفم سيئة. جميع حالات ورم الحمل كانت لها أسطح مفصصة، وأظهرت نزيفا عفويا ومستثارا. **الخلاصة:** على الرغم من أن نتائج هذه الدراسة تشير إلى أن انتشار أورام الحمل لدى النساء الليبيات الحوامل يعتبر منخفضا (1.0%)، إلا أن البرامج التثقيفية على صحة الفم مهمة جدا أثناء الحمل، وإذا لاحظت النساء الحوامل أي نمو غير طبيعي أثناء الحمل في فمهن، فعليهن استشارة طبيب الأسنان.

## INTRODUCTION

Pregnancy is a physiological condition that causes various changes throughout the female body. Gingivitis, gingival hyperplasia, pyogenic

granulomas, tooth mobility, xerostomia, and halitosis are the most common changes related to oral health during pregnancy [1, 2].

The changes progress due to an increased level of progesterone and estrogen hormones in the blood and saliva [3], as a response to the continuous production of these hormones by the corpus luteum at the beginning and the placenta afterward [4], they achieve their maximal plasma levels at the end of the last month of pregnancy [5], and the potential biological impact of them takes place in periodontal tissues during this period [6].

Increased sex steroid hormones have effects on gingival vasculature, subgingival microbiota, specific cells of the periodontium, and the local immune system during pregnancy [5, 7]. They are responsible for alterations in blood vessels during pregnancy by causing increased vascular permeability and vascular proliferation [8].

One of the gingival inflammatory changes that are increased in incidence during pregnancy is pyogenic granulomas (PG) [5], which occurs in 0.5-9.6% of pregnancies [9, 10], generally as an isolated, tumor-like expansion, particularly on the labial part of the anterior maxilla, and is known as a pregnancy tumor [11, 12].

PG may be sessile or pedunculated, range from purplish red to deep blue in color, range from a few millimeters to centimeters in size, and are usually slow-growing and asymptomatic but may interfere with chewing and lead to malnutrition in mothers [13]. A patient may notice bleeding while brushing their teeth. Sometimes severe bleeding also occurs in these injuries and causes physical and psychological complications for the patient. In some cases, the inhibition and treatment of this injury or its complications due to problems during pregnancy cause great trouble for the patient and the therapist [14].

PG arises in response to low-grade chronic irritants such as bacterial biofilm, dental calculus, and traumatic agents. Increased estrogen and progesterone concentrations during pregnancy increase the numbers of periodontopathogens in the subgingival biofilm,

particularly *P. gingivalis* and *P. intermedia* [5], reduce the host response to bacterial biofilm, increase vascular permeability, promote fluid infiltration into perivascular tissues, and promote the inflammatory response, all of which contribute to the development of the lesion [15]. The diagnosis of PG depends on clinical, histopathological, and radiographical examinations [16]. The following conditions should be considered in the differential diagnosis: hyperplastic gingival inflammation, peripheral ossifying fibroma, peripheral giant cell granuloma, hemangioma, Kaposi's sarcoma, angiosarcoma, non-Hodgkin lymphoma, and metastatic cancer. Biopsy findings are critical to establishing a definitive diagnosis [17, 18].

Histopathologically, the lesions are composed of highly proliferative vascular tissue with many channels bordered by endothelium, which can appear obliterated by erythrocytes. An inflammatory infiltration of neutrophils, plasmocytes, and lymphocytes is also seen [15]. Radiographic findings are absent in PG [19]. However, the characteristic bone loss associated with PG has been reported in a few clinical cases in India [20].

The need for surgical treatment during pregnancy should be carefully considered, given the high likelihood of PG recurrence and the possibility of regression after childbirth due to hormonal normalization. Treatment during pregnancy is generally required if the lesion causes functional or aesthetic impairment [15]. After pregnancy, however, surgical removal is recommended [21]. Curettage of the underlying tissue is advised after lesion removal, with 2 mm margins in the periphery and at a depth that includes the periosteum [22]. Controlling the bacterial biofilm is critical for preventing recurrence following treatment [21, 22].

The purpose of the current study was to assess the prevalence and characteristics of pregnancy tumors in pregnant Libyan women in Tripoli, Libya, in 2023. In an attempt to provide accurate

statistics about the prevalence of this lesion in the region.

## METHODS

### *Study design and subjects*

This descriptive cross-sectional study was performed on pregnant Libyan women referring to the National Heart Center-Tajoura, Jalea Maternity Hospital, and Tripoli University Hospital, Libya in 2023.

The participants were informed about the objectives of the study, they were also assured that their information would remain confidential, and informed consent was obtained from each one. Pregnant Libyan women were randomly selected from the waiting list of selected medical centers. Non-Libyan women, pregnant women with any mobility of the adjacent teeth, a history of malignancy, hormonal disturbance such as hyperparathyroidism, or human immunodeficiency virus infection were excluded from this study [23].

The sample size was calculated using a 5% margin of error and 95% confidence level, giving a sample size of 385 subjects [24].

### *Data collection*

The current study was conducted from August to November 2023 using a pre-validated information form [23, 24], which was modified by a periodontist and two oral pathologists and filled out through interviewing and clinical examination of the participants.

The data form recorded the age groups of participants, number of previous pregnancies, age of the fetus, tooth brushing pattern per day, use of dental floss and mouthwash, pattern of dental visits per year, consumption of oral contraceptive pills (OCPs), medical history of chronic disease, presence of tartar (calculus) in different areas, gingival bleeding, and presence of exophytic lesion on the gingiva developed any time during pregnancy.

Clinical intraoral examination of the participants was performed if a pregnancy tumor (PT) was present, and its clinical characteristics: site, the presence of biofilm or calculus, an unsuitable crown or filling at the site of lesion, pedunculated or sessile, smooth or lobulated surface, spontaneous and provoked bleeding, color ranging from pink to intense red, soft or firm in consistency, and is ulcerated or no, were reported on the data form.

### *Statistical analysis*

The collected data after completing the information form and clinical examination, were analyzed using IBM SPSS Statistics version 26.0® (IBM Corporation, New York, USA). Descriptive statistics were used to express the percentages and frequency of the categorical variables.

### *Ethical considerations*

The ethical approval for this study was obtained from the Faculty of Dentistry, University of Tripoli, dated 3/7/2023, and then from the head of the hospital of each center which in turn gave us permission to conduct the study on pregnant patients referring to selected centers before beginning the study. The identities of the participants were kept anonymous, according to the World Medical Association Declaration of Helsinki.

## RESULTS

During four months period, a total of 402 cases of pregnant Libyan women were evaluated at the National Heart Center-Tajoura, Jalea Maternity Hospital, and Tripoli University Hospital. Of these, four cases were clinically diagnosed with PT, accounting for 1.0% of the total sample.

According to age groups, 181 (45%) cases were older than 30 years old, 152 (37.8%) cases were between 24 and 29 years old, and 69 (17.2%) cases were between 18 and 23 years old.

Considering the fetal age of all subjects, two-thirds (66.4%) of subjects were in their 7<sup>th</sup> to 9<sup>th</sup> months of pregnancy, over a quarter (26.9%) of subjects were in their 3<sup>rd</sup> to 6<sup>th</sup> months of pregnancy, and only 27 (6.7%) subjects were in their 1<sup>st</sup> to 2<sup>nd</sup> months of pregnancy.

Regarding the number of previous pregnancies, above half (55.0%) of all cases were experiencing their first or second previous pregnancies, 121 (30.1%) cases experiencing their third or fourth previous pregnancies, 42 (10.4%) cases experiencing their fifth or sixth previous pregnancies. Only 18 (4.5%) cases were experiencing their seventh or eighth previous pregnancies.

In our study, the distribution of participants based on their tooth-brushing pattern is shown in Figure 1. Half (50%) of participants brush their teeth twice a day, more than one-quarter (28.9%) of participants brush their teeth once a day, 72 (17.9%) participants brush their teeth three times a day, whereas 13 (3.2%) participants do not brush their teeth at all.

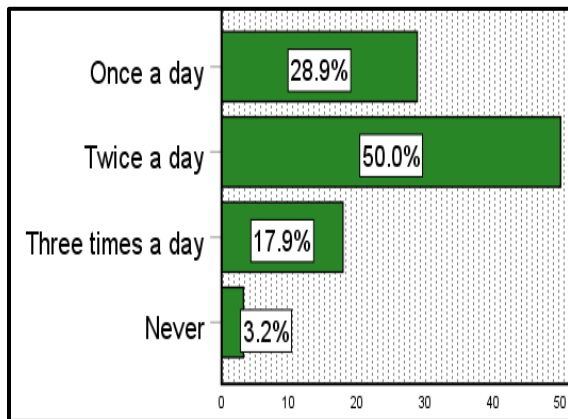


Figure 1. The tooth-brushing pattern per day of the participants (n = 402).

Considering using dental floss, one-third (33.8%) of all cases use dental floss, while nearly two-thirds (66.2%) do not. Furthermore, more than one-quarter (29.1%) of all cases use mouthwash, whereas nearly three-quarters (70.9%) of them do not use it.

Figure 2 shows the pattern of visiting a dentist per year, nearly half (48%) of all participants visit the dentist once a year, 47 (11.7%) participants visit the dentist twice a year, 37 (9.2%) participants visit the dentist three times a year or more, while nearly one-third (31.1%) never visit the dental clinic for regular check-up but for dental need.

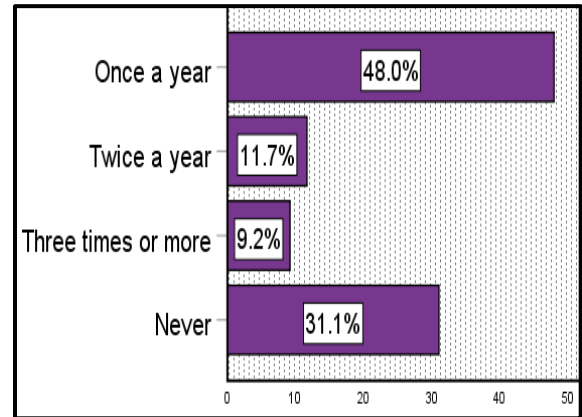


Figure 2. The pattern of visiting a dentist per year of the participants (n = 402).

Considering the consumption of contraceptive pills, most of the cases (84.6%) did not report consumption of it, while 62 (15.4%) cases have taken OCPs.

Regarding the medical history of chronic diseases in the studied sample, the majority of subjects (89.8%) have no chronic disease history, while 41 (10.2%) subjects have chronic diseases. In this sample, dental calculus was reported in 162 (40.3%) cases, and nearly half (47%) of cases had bleeding gum. While above half (59.7%) of cases and (53%) do not have calculus nor bleeding gum, respectively.

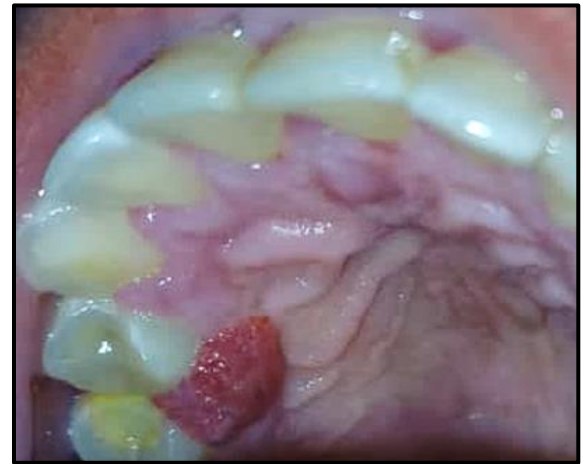Of 402 pregnant Libyan women only four cases had exophytic lesions in the gingiva, which were clinically diagnosed as PT (Figure 3). The four cases were in their third trimester (ninth month) of pregnancy. Half (50%) of cases were more than 30 years old, and the other 2 (50%) cases were 25 and 21 years old. Three of the affected cases experiencing their third or fourth previous



pregnancies, while one case had her first pregnancy. In all cases with PT brush their teeth 1-2 times/day. Three-quarters (75%) of cases do not use dental floss, and half (50%) of them do not use mouthwash. Moreover, three-quarters (75%) of PT cases visited a dental clinic more than three times a year; usually for dental needs not for regular check-ups. All PT cases do not have any chronic diseases and never use OCPs. All PT cases have calculus on their teeth, bleeding gums, and poor oral hygiene status (Table 1).

Intraoral examinations of PT cases are shown in Table 2. We reported that the only site of the lesions was the gingiva; it was observed in the maxilla among 2 (50%) of women with tumor and in the mandible among 2 (50%) of them. All lesions were sessile and had lobulated surfaces. Unsuitable crowns or filling at the site of the lesion were reported in half (50%) of PT cases. All PT cases showed spontaneous or provoked bleeding. Three (75%) of PT lesions were soft in

consistency, while one (25%) lesion was firm. The color of the lesion in half (50%) of PT cases at the time of referral was pinkish-red, whereas the other half (50%) of the lesion showed reddish color. All PT cases were not ulcerative.



**Figure 3. Intraoral photographs of PT (case 4); a sessile soft lobulated reddish lesion of upper palatal posterior gingiva.**

**Table 1. Demographic data and oral hygiene characteristics of PT cases (n = 4).**

Variable	Case 1	Case 2	Case 3	Case 4
Age of patient	>30	25	21	>30
Previous pregnancies	3-4	3-4	1	3-4
Trimester (fetal age)	3 <sup>rd</sup> (9 <sup>th</sup> month)	3 <sup>rd</sup> (9 <sup>th</sup> month)	3 <sup>rd</sup> (9 <sup>th</sup> month)	3 <sup>rd</sup> (9 <sup>th</sup> month)
Brushing \ day	Once a day	Twice a day	Once a day	Once a day
Flossing	+ ve	- ve	- ve	- ve
Mouthwash	- ve	+ ve	- ve	+ ve
Dentist visit \ year	> 3 times	> 3 times	Never	3 times
Oral contraceptive pills	- ve	- ve	- ve	- ve
Chronic diseases	- ve	- ve	- ve	- ve
Presence of calculus	+ ve	+ ve	+ ve	+ ve
Bleeding gum	+ ve	+ ve	+ ve	+ ve
Time of onset of gingival swelling during pregnancy	2 <sup>nd</sup> month	2 <sup>nd</sup> month	2 <sup>nd</sup> month	5 <sup>th</sup> month

**Table 2. Intraoral examinations characteristics of PT cases (n = 4).**

Variable	Case 1	Case 2	Case 3	Case 4
Site of lesion	Lower posterior gingiva	Upper anterior gingiva	Lower anterior gingiva	Upper posterior gingiva
Pedunculated \ sessile	Sessile	Sessile	Sessile	Sessile
Smooth \ lobulated surface	Lobulated	Lobulated	Lobulated	Lobulated
Unsuitable crown \ filling at the site of lesion	+ ve	- ve	- ve	+ ve
Spontaneous & provoked bleeding	+ ve	+ ve	+ ve	+ ve
Consistency	Soft	Firm	Soft	Soft
Color	Reddish	Pinkish-red	Pinkish-red	Reddish
Ulceration	- ve	- ve	- ve	- ve

## DISCUSSION

This study aimed to investigate the prevalence of PT among pregnant women in Tripoli, Libya from August to November 2023. Based on the findings, the frequency of PT was reported as 1.0% (4 cases of 402 pregnant women had clinical signs and symptoms of PT).

Negad *et al* [23] reported that the prevalence to be 0.22%, which is the lowest reported prevalence in the literature, the possible explanation is their cases were confirmed histologically by biopsy. Molania *et al* [24] reported that the prevalence to be 4.38%, which is consistent with 4.5% reported by Khatibi *et al* [25], both studies were among pregnant women in Iran and these frequencies were higher than ours. Sá de Lira *et al* [26] examined 102 pregnant women, and the prevalence of PT was 1.96%, which is consistent with our results. Arivaruliyar *et al* [27] conducted a systematic review of 6 studies that investigated the prevalence of PT and concluded that the prevalence of PT is 2.15% - 3.70%, which is comparable with our findings.

In the present study, above half of the participants do not have calculus, half of them brush their teeth twice a day, one-third of cases use dental floss, more than one-quarter of cases

use mouthwash and most cases have reasonable oral hygiene. In addition, most cases did not report consumption of OCPs and chronic disease history, so the hormonal imbalance during pregnancy is only the predisposing factor in most participants which explains the low prevalence of PT lesions.

In the current study, half PT of cases were >30 years old, and other half were early 20 years old. The average age of PT cases reported by Khatibi *et al* [25], and Sasan *et al* [28] were 26.8, and 28 years old, respectively. According to Molania *et al* study [24], there is a significant relationship between younger age and the presence of PT.

In our study, PT was found in the ninth month of pregnancy where progesterone and estrogen hormones reach peak levels during this period [3-6]. Sá de Lira *et al* [26]. reported that all cases were in their third trimester, this was comparable to our results. While, Molania *et al* [24] and Sasan *et al* [28] studies have some positive cases in second trimester of pregnancy. All PT cases have calculus on their teeth and poor oral hygiene status due to low frequency of teeth brushing and not using dental floss and mouthwash, which are among the most common predisposing to PT [5]. This result is consistent with most previous studies [15, 16, 24,

26], which reported a significant correlation between PT and oral hygiene status.

Unsuitable crowns or restorations at the site of the lesion were found in half (50%) of PT cases. Molania1 *et al* [24] demonstrated a significant correlation between inappropriate restoration or dental crowns and epulis gravidarum. Also, Khatibi *et al* [25] reported nine positive PT cases of 72 cases found near defective restorations and crowns.

The only site of lesions in this study was the gingiva and presence of PT in the maxilla was as same as in the mandible According to previous studies, the gingiva is the most affected site and the maxillary lesions are more prevalent [15, 16, 23,25, 28].

In the present study, all patients with PT showed signs of bleeding and most lesions are reddish and hemorrhagic because they are composed of hyperplastic granulation tissue in which capillaries are prominent [8], so minor trauma to the lesions may provoke considerable bleeding [26]. This sign is consistent with the findings of previous studies [24-27].

The limitation of our study is the lack of histological confirmation of the diagnosis by biopsy because; it needs the obtaining patient consent for biopsy, a high likelihood of PT recurrence if excised during pregnancy, and the possibility of regression after childbirth due to hormonal normalization [15,21]. However, the participants in this study were selected from large governmental hospitals in Tripoli, Libya, which are a good representative of Libyan population.

## CONCLUSIONS

The results of this study indicate that the prevalence of pregnancy tumors in pregnant Libyan women is considered low (1.0%), Preventing this tumor during pregnancy is simple by maintaining good oral health and using preventive measures. Therefore, pregnant

women should consult a dentist, if they notice any abnormal growth during pregnancy in their mouth.

Gynecologists are primary health-care providers for pregnant women, so a future cross-sectional study is needed to evaluate the knowledge and awareness of gynecologists regarding oral health during pregnancy in Tripoli, Libya.

## Conflict of Interest

There are no financial, personal, or professional conflicts of interest to declare.

## REFERENCES

1. Naseem M, Khurshid Z, Khan HA, Niazi F, Zohaib S, Zafar MS. Oral health challenges in pregnant women: Recommendations for dental care professionals. *The Saudi Journal for Dental Research*. 2016;7(2):138-46.
2. Fakheran O, Keyvanara M, Saied-Moallemi Z, Khademi A. The impact of pregnancy on women's oral health-related quality of life: a qualitative investigation. *BMC Oral Health*. 2020;20:1-1.
3. Paradowska AN, Sławewski KO, Gwiazda-Chojak E. Pregnancy Tumor—Review of the Literature. *Dent. Med. Probl*. 2008;45(1):51-4.
4. Markou E, Eleana B, Lazaros T, Antonios K. The influence of sex steroid hormones on gingiva of women. *The open dentistry journal*. 2009;3:114.
5. Güncü GN, Tözüm TF, Çaglayan FE. Effects of endogenous sex hormones on the periodontium—review of literature. *Australian dental journal*. 2005;50(3):138-45.
6. Apoorva SM, Suchetha A. EFFECT OF SEX HORMONES ON THE PERIODONTIUM. *Indian Journal of Dental Sciences*. 2010;2.
7. Wu M, Chen SW, Jiang SY. Relationship between gingival inflammation and pregnancy. *Mediators of inflammation*. 2015;1-15.
8. Bhardwaj A, Bhardwaj SV. Effect of androgens, estrogens and progesterone on periodontal tissues. *Journal of Orofacial Research*. 2012;2(3):165-70.

9. Mealey L, Moritz J. Hormonal influences on periodontium. *Periodontology* 2000 2003;32:59-81.
10. Silk H, Douglass AB, Douglass JM, Silk L. Oral health during pregnancy. *Am Fam Physician* 2008;77(8):1139-44.
11. Sun WL, Lei LH, Chen LL, Yu ZS, Zhou JW. Multiple gingival pregnancy tumors with rapid growth. *Journal of Dental Sciences*. 2014;9(3):289-93.
12. Gondivkar SM, Gadbaile A, Chole R. Oral pregnancy tumor. *Contemp Clin Dent*. 2010 Jul;1(3):190-2.
13. Marla V, Shrestha A, Goel K, Shrestha S. The Histopathological Spectrum of Pyogenic Granuloma: A Case Series. *Case Rep Dent*. 2016;2016:1323798.
14. Naghi I, Keypour F. Pyogenic Granuloma in Pregnancy: A Case Report. *J Babol Univ Med Sci*. 2019;21:153-6.
15. Cardoso JA, Spanemberg JC, Cherubini K, Figueiredo MA, Salum FG. Oral granuloma gravidarum: a retrospective study of 41 cases in Southern Brazil. *J Appl Oral Sci*. 2013;21(3):215-8.
16. Alwan AH, Zardawi FM, Gul SS, Hussain AA. Prevalence and Distribution of Gingival Pyogenic Granuloma in Sulaimani population-Kurdistan Region-Iraq. *Biomedical and Pharmacology Journal*. 2018;11(1):105-11.
17. Tomasz Gęca, Maciej Kwiatek, Arkadiusz Krzyżanowski, Anna Kwaśniewska. A large oral pregnancy tumor – case report. *GinPolMedProject*. 2018;1(47):038-040.
18. Rihani FB, Ersheidat AA, Alsmadi HF, et al. Multiple long-standing massive oral mandibular granuloma gravidarum (pregnancy tumour): A Case Reports. 2013;2013:bcr2013010182.
19. Kamal R, Dahiya P, Puri A. Oral pyogenic granuloma: Various concepts of etiopathogenesis. *J Oral Maxillofac Pathol*. 2012;16(1):79-82.
20. Lomelí Martínez SM, Bocanegra Morando D, Mercado González AE, Gómez Sandoval JR. Unusual clinical presentation of oral pyogenic granuloma with severe alveolar bone loss: A case report and review of literature. *World J Clin Cases*. 2023;11(16):3907-14.
21. Gondivkar SM, Gadbaile A, Chole R. Oral pregnancy tumor. *Contemp Clin Dent*. 2010;1(3):190-2.
22. Gadea Rosa C, Cartagena Lay A, Cáceres La Torre A. Oral pyogenic granuloma diagnosis and treatment: a series of cases. *Revista odontológica mexicana*. 2017;21(4):253-61.
23. Nejad ES, BigomTaheri J, Azimi S. Frequency of gingival pregnancy tumor in iran (confirmed by biopsy). *J Int Oral Health*. 2014;6(6):72-6
24. Molania T, Salehabadi N, Zahedpasha S, Yazdani J, Imani B, Ghasemi S, et al. Frequency of epulis gravidarum in pregnant women in Sari and Ghaemshahr cities in Iran in 2020. *J Nurs Midwifery Sci*. 2022;9:303-9.
25. Khatibi M, Niromanesh S, Abhari SY, Falakaflaki N. Prevalence of pregnancy tumor (Pyogenic Granuloma) and related factors in pregnant women referred to Tehran Mirza Kuchak khan hospital during 2010-2011. *Iran J Obstet Gynecol Infertil*. 2013;16:1-6.
26. Sá de Lira AD, Silva NR, Caetano VD, Araújo Junior AG, Portela IJ. Prevalence and etiological factors of Piogenic Granuloma in gestants. *Braz. dent. sci*. 2019;22(4):443-9.
27. Arivaruliyar, Maragathavalli G, Sangeetha P. Prevalence of pyogenic granuloma in pregnant womens, A Systematic Review. *International Journal of Current Research*. 2016;8(10):40594-97.
28. Sasan NS, Kaul R, Jain P, Angrish P, Arora K, Pable SL. A research analysis on pregnancy tumor-correlation with pyogenic granuloma. *Int J Health Sci Res*. 2016;6(2):208-12.